

The Anatomy of Selected Joint Locks

Hien N. Nguyen

Introduction

My initial foray into martial arts came when my dad took me to an aikido dojo in the Little Saigon district of Westminster. We arrived in time to watch the weekend youth class warming up. I watched as the instructor led the excitable students through trips of rolls and falls across the mat. I had never seen any of these techniques performed before, and watched in fascination as other kids my age rolled nimbly and effortlessly, forwards, backwards, or even after flying through the air. Being the shortest and smallest seventh grader in my class, I was a little intimidated when my dad first suggested I take up martial arts. After seeing kids having fun with nothing reminiscent of the Cobra Kai school in *The Karate Kid*, though, I said I might like to try it out.

As we stayed to watch the remainder of class and warm-ups ended, the students all knelt in a line along one length of the mat. The head instructor, Sensei Dang Thong Phong came out, called upon the senior black belt, and proceeded to demonstrate aikido techniques, three different ones for varying skill levels of the class. Each time, as the black belt reached to grab his wrist, Sensei Phong would turn like a bullfighter, leading his attacker around in a flurry of

off-balanced steps before throwing or directing the black belt to the ground with manipulations of his hand or arm. Even with my untrained eye, it was evident that these techniques were performed with simple, elegant twists and turns of the arms and hands. As a youngster, I had seen my share of playground contortionists who could demonstrate feats of flexibility that would unnerve any mother who saw. But here, kids swiftly (and sometimes gleefully) locked up each other's shoulders, elbows, and wrists, with efficient movements. I realized if these techniques could work on the Gumby-limbs of my peers, they could work on anyone, a fact that has become more painfully evident as I've gotten older.

I never thought too much about why wrist techniques worked while I practiced aikido through high school. I could tell when a technique was effective on me and would simply try to duplicate the experience for my partner when I executed it. This allowed me some comprehension of locks, holds, and controls, but any insight into what was happening structurally was limited to the most intuitive observations. This allowed me to develop my techniques to meet the casual ambitions I had at the time, though, so I was satisfied. After coming to college and having started my career in Hankido, I wanted martial arts not to be an isolated activity in which to challenge myself, but I wanted to apply it as a part of learning and growing in general. Wanting more out of practicing martial arts, I realized I had to put more in.

While helping Dr. Ken Min teach his UC Berkeley Hankido physical education classes, I was often asked

why one manipulates an arm or hand a certain way for a given technique. Initially, I gave no verbal responses and simply demonstrating on the students instead. When there were wincing of pain, eyes opened wide, and lips mouthed “O,” I knew there was some comprehension. As this continued, though, I grew dissatisfied with not knowing myself exactly why some techniques were painful or effective locks. Hence, the premise of this paper: what is the relationship between joint anatomy and the effectiveness of various wrist techniques? While such knowledge is not necessary to learn proper execution of these techniques, I felt greater insight could only deepen my appreciation of what I was doing.

There are many types of joints in the arm and hand, and these allow for specific types of movement. The structures of these joints balance stability and strength with mobility and flexibility. Joints must make tradeoffs between these two aspects, and wrist techniques exploit their shortcomings to cause pain, threaten injury, or immobilize.

Joints and Joint Structure

Technically, joints are simply where separate, rigid parts of the skeleton meet in one way or another. Although not always immediately associated with joints because they are rigid, such articulations as the sutures between the bones of the skull are joints, as are bones held together in place by ligaments, but not designed to move, such as where the tibia and fibula articulate. Where two bones are separated by cartilage, some movement may be allowed, such as in the

vertebrae. In other cases, bone movement can be largely absent, such as between the ribs and the sternum. The most movable joints, and those we will be most concerned with, however, are synovial joints. These are the joints that one most often associates with the term, and they allow the greatest mobility exhibited by our bodies. These joints are named for the fluid, synovia, which cushions the articulating bones and allows for their characteristic flexibility. Synovial fluid contains special proteins which provide its slippery, lubricating nature.¹

The movement and flexibility of synovial joints are allowed by their structure. Where the bones come together, the ends are protected by articular cartilage, spongy coverings which absorb compression between the bones and prevent damage to the bone ends.² Surrounding the joint is the articular capsule, which links together the two bones and encloses the synovial cavity, the space in which synovial fluid separates the articulating bones.³ Externally, this capsule is made of fibrous connective tissue, which binds the joint. Internally, the synovial membrane consists of looser connective tissue, which is in contact with the synovial fluid and covers any bone surfaces not covered by articular cartilage. Aside from cushioning, synovial fluid also seeps into the articular cartilage to lubricate and nourish its cells.⁴ To provide support and stability, ligaments reinforce the joint, running within the articular capsule matrix, outside the capsule, and even within the joint cavity itself.⁵ Lastly, the joint is richly innervated throughout the articular capsule, monitoring both pain and degree of capsule stretch.⁶ Joints are also stabilized by muscle tendons

just external to their capsules,⁷ which are also innervated to monitor position and stretch.⁸ The receptors for these nerves—various joint kinesthetic receptors—detect rapid movements and accelerations of joints, monitor position and slow stretches, and respond to pain.⁹

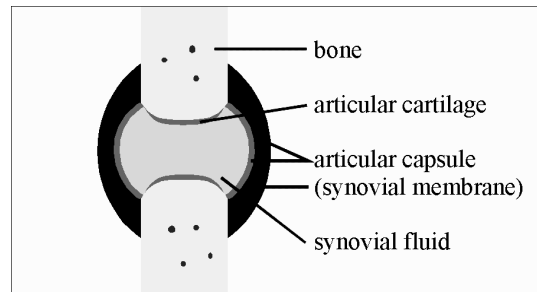


Figure 1: General synovial joint structure

Though synovial joints allow the greatest mobility and flexibility of all joints, they are also the most vulnerable links in the skeleton. Naturally, martial arts techniques often focus directly on these joints for controls, locks, and application of pain.

The Upper Limb: Joint Types, Movements, and Vulnerabilities

The bone arrangement in the arm and hand is quite simple for our purposes (see Figure 2). The scapula, or shoulder blade, nestles one end of the humerus, creating the shoulder joint. The humerus extends from the shoulder to the elbow, where it articulates with the two bones of the forearm: the radius and the ulna. These two bones connect the elbow to the wrist. With the arm hanging down with palm facing the same direction as the bellybutton, or ventrally, the

radius and ulna lie alongside each other, with the ulna lying nearest the body, from elbow to pinky side of the wrist; the radius runs towards the thumb. At the wrist, the radius meets two of the eight small carpal bones. The carpals make up the palm's "heel," and are arranged essentially in two rows of four bones. The distal (further from the spine) four carpals articulate with the five metacarpals, the long, slender bones of the palm connecting the fingers to the carpals. Each metacarpal articulates with a phalanx (the singular form of "phalanges") forming the knuckles. Each finger except the thumbs has a proximal (nearer to the spine), middle, and distal phalanx, making the three finger segments. The thumb lacks a middle phalanx.

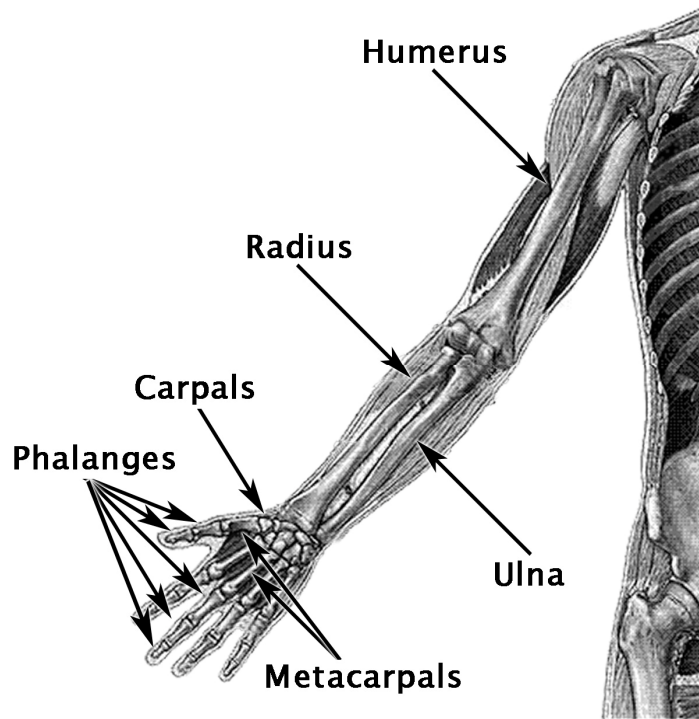


Figure 2: General articulation of the arm bones.¹⁰

The surfaces between the articulating bones determine how joints function in their movement. Marieb and Mallatt (1997) describe six characteristic synovial joint types: plane, hinge, pivot, condyloid, saddle, and ball-and-socket.¹¹ All six can be found within the wrist-elbow-shoulder unit. Together, these joints allow the arm and hand amazing mobility and dexterity. Taken in isolation, though, each joint allows only certain types of movement. This is a key point underlying why wrist techniques work.

In plane joints, bones meet at fairly flat surfaces, and movement occurs as the two faces or planes glide past each other. This is akin to two flat hands pressed and rubbed against each other. Of interest to wrist techniques, plane joints are found between carpal bones, and between the carpals and metacarpals – virtually all of the wrist.¹² Plane joints cannot rotate along any axis, and are therefore perhaps the synovial joints with the least mobility.

The elbow is an example of a hinge joint,¹³ with the ulna bearing a trough-like ridge, which nestles the cylinder-like end of the humerus. This allows the swinging flexion and extension of the forearm at the elbow. Though quite stable, hinge joints can only allow a wide range of motion within a specific plane. With the upper arm held still, one can only swing the forearm in a single arc, the plane of which is determined by the orientation of the upper arm. Also, the elbow can only extend to where the arm is approximately straight, whereupon the ulna can not move further without elbow injury.

With the elbow held still, the forearm can still twist back and forth, which is allowed by a pivot joint

between the proximal (closer to the spine) ends of the radius and ulna.¹⁴ Here, a ring of ligament attached to the ulna allows longitudinal rotation of the radius. This is the joint used to change forearm orientation from “thumb up” to “thumb down.” When the two bones are brought parallel—thumb up—the arm movement is called supination; pronation brings the radius to cross the ulna—thumb down.

In condyloid joints, the concave surface of one bone articulates with the convex surface of another bone allowing flexible movement back and forth and side to side like a joystick, but virtually no rotation is enabled. Condyloid joints are found in the knuckles and between where the radius meets the carpals.¹⁵ This may be surprising, because intuitively, it may seem that the wrist can rotate when it actually can not. Consisting only of plane joints in the carpals, and a condyloid joint between radius and carpals, the wrist itself is allowed essentially no longitudinal rotation. Try holding your forearm still with the other hand: the wrist can move back and forth, rock side to side, but there’s no switching from thumbs up to thumbs down.

The carpometacarpal joint of the thumb is a saddle joint, where both articulating bone surfaces are shaped like saddles, and nestle in one another.¹⁶ Saddle joints allow essentially the same movements as condyloid joints. However, the thumb can be twisted slightly by another hand, due perhaps more to the looseness and flexibility of the joint than its natural articulation.

Lastly, in the shoulder, the round head of the humerus and the cupped surface of the scapula is an

example of a ball-and-socket joint.¹⁷ The shoulder can move back and forth, side to side, and rotate. Ball-and-socket joints are the most flexible, but also the most easily dislocated. The shoulder is especially vulnerable, since its extreme range of flexible motion is allowed by sparse support from the bone structures themselves; the joint relies greatly on tendons for stability and support. The fact that the articular capsule of the joint and its associated ligaments are extremely thin also contributes to the great mobility and vulnerability of the shoulder joint.¹⁸

Again, the upper limb combines the six basic joint types, allowing a complex, infinite variety of movements of the arm and hand. However, when taken individually, each joint is limited in the movement it allows, making each individual joint less flexible than the limb as a whole appears to be. This lack of flexibility can be a potential subject of attack or control in terms of wrist techniques. The shoulder, in allowing its great flexibility, is less strong and is easily dislocated, making it also vulnerable to attack and control.

Care must be taken when practicing wrist techniques to prevent joint injuries, especially sprains and dislocations. Sprains occur when joint ligaments are overstretched, torn, or even completely ruptured. Without prompt surgical repair of ruptured ligaments, serious, irreversible damage will occur.¹⁹ Even partially torn ligaments can be quite painful, and are slow to heal. Dislocations occur when joint bones are forcibly displaced from their proper alignment. Dislocations are often accompanied by sprains, pain, and inflammation.²⁰ With the upper limb, the shoulder and

digits are the two locations most prone to dislocation,²¹ which can be attributed to their structural emphasis on mobility and flexibility. Joints are at greater risk of dislocation when ligaments are overstretched.²² Ligaments can take years to readjust after being stretched and can only stretch about 6% beyond rest length before rupturing.²³

Analysis of Techniques

The Basic Wrist Lock, Kote Gaeshi

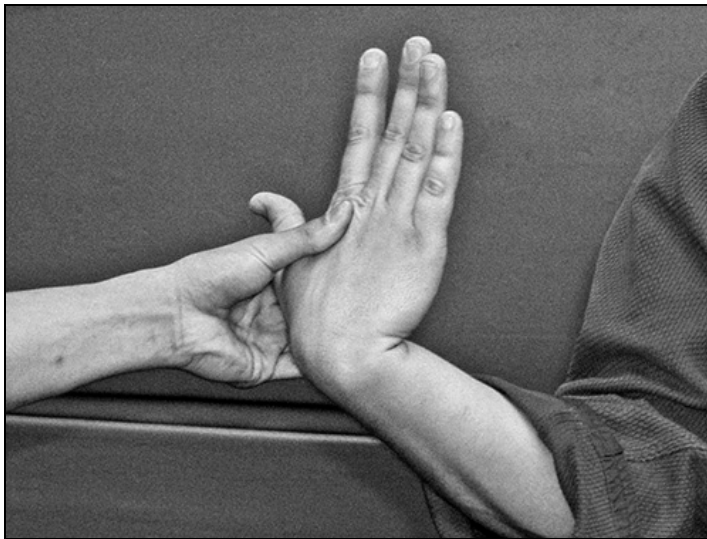

Figure 3: Holding the wrist in locked position.²⁴

With wrist techniques, different schools teach different approaches and with different emphases. However, some techniques are fundamentally the same between many schools. One of the first wrist techniques I was exposed to in Hankido is analogous

to the position Jujitsu Professor Wally Jay describes as “basic wrist lock”.²⁵ I had practiced this same technique in aikido as *kote gaeshi*.²⁶ This technique involves locking the wrist through manipulation of the hand (Figure 4).

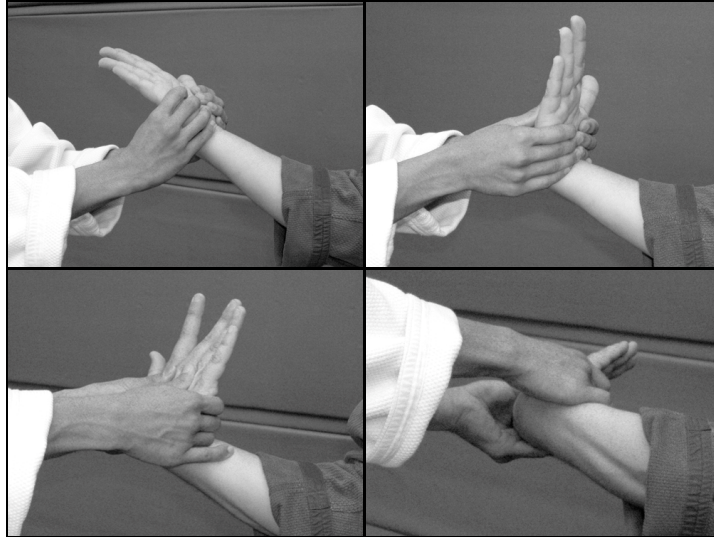


Figure 4: An execution of *kote gaeshi*.

From a grip on the hand (and the grip may vary), many things are done simultaneously. The forearm is supinated (rotated in the “thumbs up” direction) to remove rotational slack below the elbow. The elbow is flexed so that the forearm becomes approximately perpendicular to the humerus. The wrist is flexed toward the forearm, and the palm is turned in the same direction that supination occurs.

In this position, many factors contribute to an effective lock on the wrist. The forearm is supinated to the limit of the radioulnar joint in the elbow. However, if the arm were left straight, the shoulder joint could rotate and absorb some of the arm twist

that the elbow alone cannot. This is why the elbow is flexed to 90°; with the arm in this position, the shoulder joint cannot alleviate twisting of the forearm. With the forearm thus supinated, further twisting of the hand stresses the various wrist joints as they bear pressures and forces not allowed by their natural motion. The wrist is still capable of other movements, though, and pressure can be taken off the wrist by proper evasive techniques or resistance. Hence, flexion of the wrist is used to limit the back and forth motion of the wrist, and turning the palm in the direction of supination removes the last bit of slack. From here, further pressure on the lock will force the recipient either to compromise his or her balance, or to accept injury to the wrist.

Anatomically, it can be seen that when properly performed, this technique, in order to overcome the large degree to which the arm can be rotated, isolates the wrist as the target of rotation. When executed as described above, the wrist is what is attacked, so the mobility of the shoulder and elbow are prevented from aiding the wrist. As seen in figure 3, one can twist the hand itself to maximize the tightness of the wrist twist. The executor's thumb is placed firmly on the back of the recipient's hand and the executor's fingers grip around the base of the recipient's thumb. From here, the executor's left hand in figure 3 can push with its thumb and pull with its fingers while also executing the technique to lock out the recipient's carpometacarpal joints and the thumb.

The Bent-Elbow Wrist Lock, Nikyo



Figure 5: An execution of nikyo.

One of my favorite locks from aikido, nikyo,²⁷ is almost like a reverse version of kote gaeshi. Jay describes this technique as “bent elbow wrist lock.”²⁸ I liked the versatility of this technique, for it can be a swift, efficient defense to many attacks. Westbrook and Ratti describe three ways in which to perform this lock: against the shoulder (Figure 6), with the hands alone (Figure 7), and about one’s own wrist.²⁹ The effect on the recipient’s wrist is largely the same.




Figure 6: Performed against the shoulder.

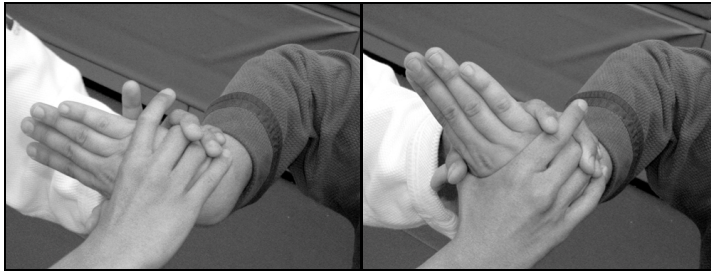


Figure 7: Performed with the hands only.

The twisting of the forearm for this lock is pronation (the direction for “thumbs down”) as opposed to the supination for the previously discussed technique. The hand is flexed toward the forearm, and then used as a handle to pronate the forearm. Again, the elbow is bent approximately perpendicular to the upper arm so the shoulder cannot lend its own rotation to relieve the twisting from forearm pronation. From here, the hand is twisted in the direction of pronation, while the forearm optionally twisted the other way. This can be achieved by using the recipient’s elbow as the end of a lever to crank the forearm (fig. 4). As another option, both of the executor’s hands can grip the recipient’s if the recipient is particularly strong or with big hands. here, the countertorque of using the elbow as a lever is lost, but the grip on the recipient’s hands is stronger.

Again, being isolated from the elbow and shoulder by the initial manipulations means that the wrist is the sole focus of the twisting pressure exerted in the technique. Keep in mind that the shoulder can rotate longitudinally with its ball and socket joint, and the elbow allows the forearm to rotate via the pivot joint between the radius and ulna. By bending the arm into

a chicken-wing shape at the elbow, neither of these rotational capacities can be used to alleviate the pressure on the wrist that results from proper application of this technique. Since the wrist joints don't allow the wrist itself to twist, the efficacy of this technique is not surprising.

The Four-Corner Throw, Shiho Nage




Figure 8: Two views of the arm in shiho nage.

Whereas the previous two techniques were essentially wrist-isolation locks, shiho nage, meaning “four-corner throw”,³⁰ can control the hand, wrist, elbow, and shoulder. Although there are variations in which pressure may be taken off any of those elements (most often out of safety concerns), the most powerful and elegant execution is when the recipient is held as depicted in final panel of Figure 9. The hand is used as a lever to twist the wrist; the executor's arm levers the recipient's elbow upwards to wrench the recipient's shoulder. Executed properly, this technique threatens the wrist, elbow, and shoulder while neutralizing the recipient's arm mobility.

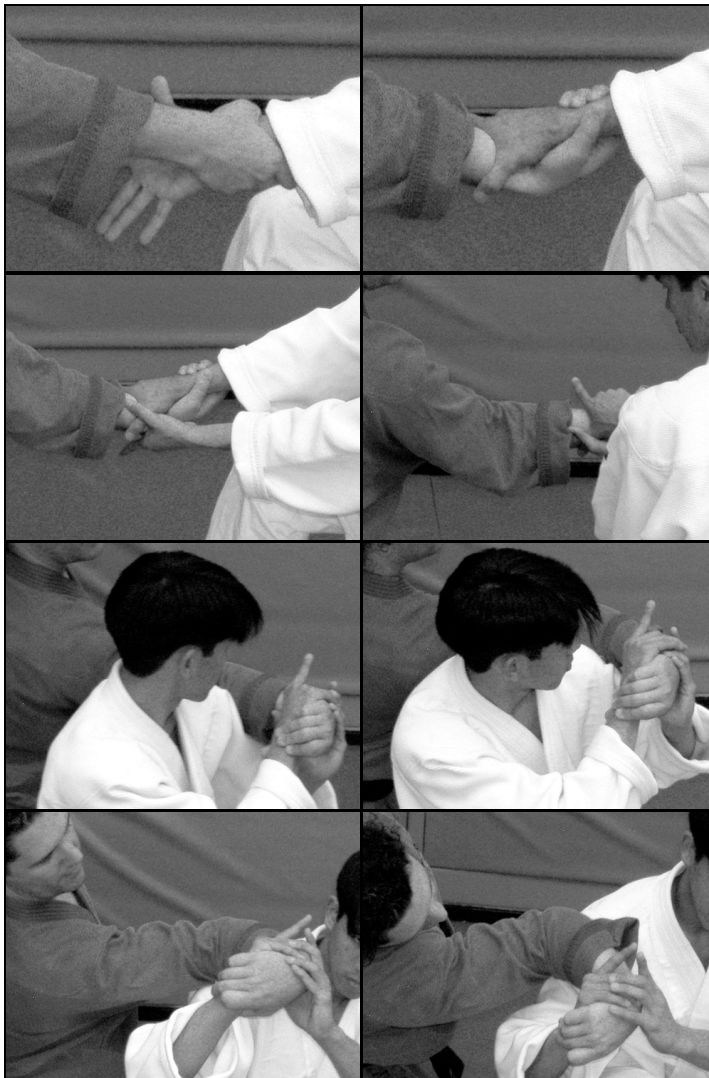


Figure 9: Execution sequence for shiho nage.

The pressure on the wrist can be similar to that created in kote gaeshi. Again, the wrist joints do not allow twisting, and this vulnerability is exploited. In addition to this pressure on the wrist, this technique also puts significant stress on the elbow. This comes

from torquing the forearm like a propeller blade about the axis of the humerus. Although the elbow does allow twisting, this technique can twist it beyond the joint's range of motion. In addition, the cumulative stress generated at the shoulder by the sum of these spiraling twists threatens to dislocate the joint inferiorly where its reinforcements are weakest.³¹

Since it can be dangerous if executed or received improperly, mollifying variations are useful for practicing this technique. When performed normally, the hand and forearm rotate in a different plane than the forearm and upper arm (Figure 10). In the first image in Figure 10, the recipient's hand and forearm are rotated clockwise as seen from above by the executor's hands. In the second image, the forearm and upper arm are rotated up and towards the reader by the executor's forearm leveraging upwards on the recipient's elbow. As these two rotations are executed simultaneously, the recipient's body cannot react to accommodate both of these torques at once, making it a potentially brutal technique.

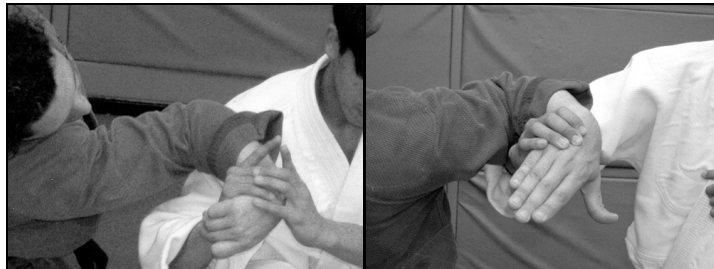

Figure 10: Different planes of rotation.

To reduce the risk of dislocating the shoulder or spraining the wrist or elbow, the wrist and elbow

should still be flexed, but keep the hand, forearm, and upper arm in a single, vertical plane (Figure 11). This allows the elbow to remain within its hinge joint's natural bend and drastically reduces risk of shoulder injury by reducing the twists imparted on it. The shoulder is no longer rotated or abducted, and the humerus is no longer pulled downwards from the shoulder joint where dislocation is likeliest.

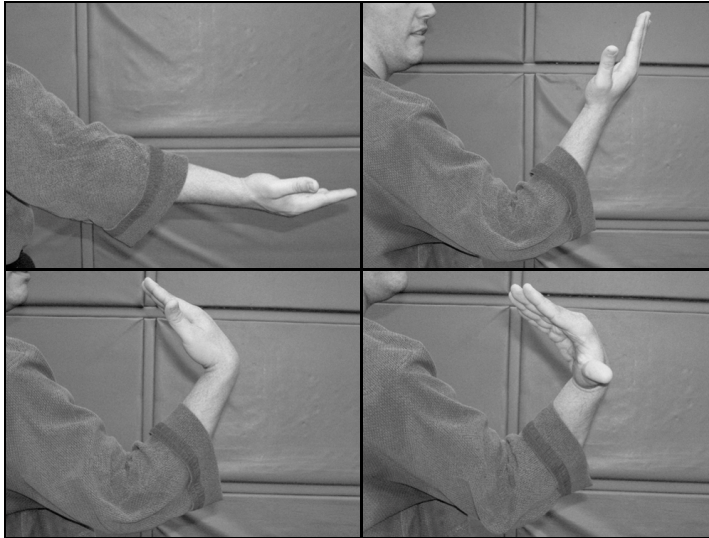


Figure 11: The first three panels show how only flexing the wrist and elbow keep the arm in a single plane, whereas the fourth panel shows the position as demonstrated in the final frames of Figure 9 & Figure 10.

Conclusion

My initial aim of studying the link between anatomy and wrist technique execution was to improve my understanding of the anatomical basis

which underlies the effectiveness of wrist techniques. Some joint attacks, such as arm bars, which simply force single joints in the wrong direction, are not hard to conceptualize and understand. I knew how to perform the techniques discussed in this paper passably long before joining U.C. Berkeley's Hankido program. Understanding more fundamentally how each works, though, I can both execute them better and teach them more effectively. However, the martial arts are still rife with techniques where anatomical and physiological analysis could provide deeper insights into how to train and perform better.

References

- Jay, Wally. *Small-Circle Jujitsu*. Santa Clarita, CA: Ohara Publications, Incorporated, 1989, ISBN# 0897501225.
- Marieb, Elaine Nicpon, and Jon Mallatt. *Human Anatomy*, 2nd Edition. Menlo Park, CA: Benjamin Cummings, 1997, ISBN# 96007345
- Westbrook, Adele, and Oscar Ratti. *Aikido and the Dynamic Sphere: An Illustrated Introduction*. Rutland, VT & Tokyo, Japan: Charles E. Tuttle Company, 1970, ISBN# 0804800049.

Endnotes

- ¹ Marieb and Mallatt, p. 193.
- ² *Ibidem*, p. 191.
- ³ *Ibidem*, p. 191-193.
- ⁴ *Ibidem*, p. 193.
- ⁵ *Ibidem*.
- ⁶ *Ibidem*.
- ⁷ *Ibidem*, p. 198.
- ⁸ *Ibidem*, p. 365.
- ⁹ *Ibidem*, p. 367.
- ¹⁰ Illustration adapted from the UNC Biology 45 self-test graphic posted at <http://tinyurl.com/6753j>.
- ¹¹ Marieb and Mallatt, p. 198.
- ¹² *Ibidem*.
- ¹³ *Ibidem*.
- ¹⁴ *Ibidem*, p. 199.
- ¹⁵ *Ibidem*.
- ¹⁶ *Ibidem*.
- ¹⁷ *Ibidem*.

¹⁸ *Ibidem*, p. 201-202.

¹⁹ *Ibidem*, p. 208.

²⁰ *Ibidem*.

²¹ *Ibidem*.

²² *Ibidem*.

²³ *Ibidem*, p. 194-195.

²⁴ All photographs by Ting Vogel, © 2004.
Higher resolution color photographs can be found at
http://www.funfolks.net/UCMAP_M6/Nguyen.

²⁵ Jay, p. 74.

²⁶ Westbrook and Ratti, p. 216. or Westbrook and Ratti, p.
174-175.

²⁷ Westbrook and Ratti, pp. 207, 209.

²⁸ Jay, p. 77.

²⁹ Westbrook and Ratti, p. 174.

³⁰ Westbrook and Ratti, p. 206.

³¹ Marieb and Mallatt, p. 202.